

Painful Non-healing Wounds In A 97-Year-Old Patient: Could It Be Angiosomal?

By Carol Ott MD FRCPC, Kennedy Ayoo MD, Andrea Moser MD MSc CCFP FCPC (COE) CMD and Giuseppe Papia MD MSc FRCSC FRSCS

How to cite: Ott C, Ayoo K, Moser A, Papia G. Case Report: Painful non-healing wounds in a 97-year-old patient: Could it be angiosomal? Wound Care Canada. 2023;21(1):15-18. DOI: [10.56885/GFRE8901](https://doi.org/10.56885/GFRE8901).

The Patient

A 97-year-old female resident of a long-term care facility presented to the Wound Care Clinic with two painful ulcers on her left foot that had appeared in the previous two months. On her 5th toe she has a small .8 x .8 cm wound that showed exposed bone (see Figure 1). On her heel she had a small wound (see Figure 2).

Past medical history included hypertension, asthma, hypothyroidism, osteoarthritis, B12 defi-

ciency and psoriasis on the soles of her feet. Her medications included: acetaminophen, amlodipine, enalapril, calcium carbonate, fluticasone 250mcg inhaler, clobetasol cream and Vitamin B12 100mcg IM monthly. Hydromorphone was used with limited success to relieve the pain.

Prior to developing these painful wounds, the patient was attending many recreational activities in the home and would go for daily walks around the facility with her friend. She was able to ambulate using her walker and had no cognitive impairment.

With the onset of the wounds, her mobility declined, notably her ability to ambulate outside

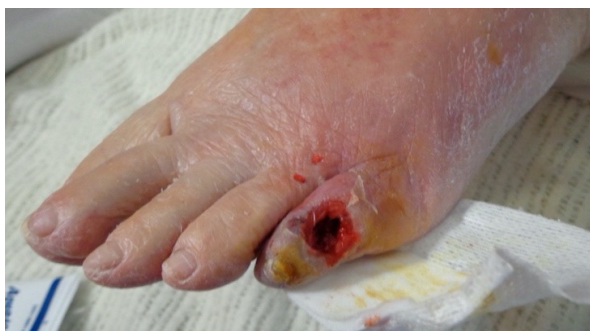

Figure 1. Left 5th toe wound.

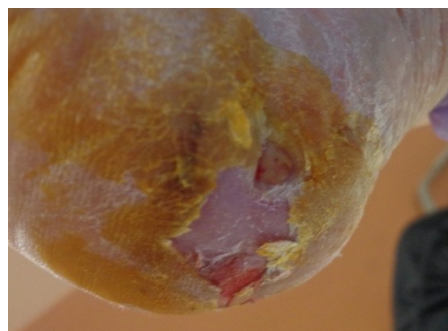


Figure 2. Left heel wound.

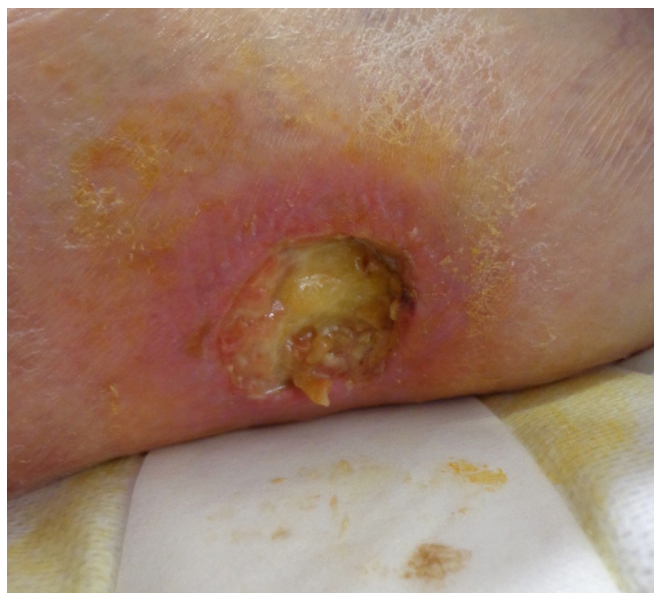

Figure 3. Left calf wound.

of her room. She remained independent in the other Activities of Daily Living (ADLs), notably dressing, eating, toileting and personal care and received minimal assistance with bathing.

She was now spending most her time in her room, sitting in a recliner. The home and family did most of the Instrumental Activities of Daily Living (IADLs) for her and she was able to phone others with the landline phone in her room (see Table 2). Family members brought forth concerns about the impact of the wounds on her activity level and on her mood.

The wound on the left 5th toe became infected. Treatment of the wounds consisted of several courses of antibiotics and topical dressings. Three months into treatment, a third painful wound appeared on her left calf (see Figure 3).

She was referred to a Vascular Surgeon six months into treatment as the wounds were not healing and continued to cause pain.

The Issue

Peripheral arterial disease (PAD) is usually caused by atherosclerosis that leads to stenosis or blockage of the major vessels supplying the lower extremities.¹ This constriction impedes blood flow to the legs and can result in symptoms such as pain, cramping and weakness, particularly during physical activities. Approximately 10% of the

worldwide population have peripheral vascular disease though the prevalence increases as we age,² making age the greatest risk factor for PAD (see Table 1).

Table 1. PAD Prevalence and Age

Age	PAD prevalence
60-69	7.0% (95% CI=5.6-8.4%)
70-79	12.5% (95% CI=10.4-14.6%)
80 and older	23.2% (95% CI=19.8-26.7%)

Source: Data from the National Health and Nutrition Examination Survey 1999-2004.³

Other Risk Factors For PAD

Additional risk factors for PAD include:³

- Current smoking
- Previous smoking
- Diabetes mellitus
- Decreased kidney function
- C-reactive protein > 3.0
- Hypertension

Symptoms Of PAD

Some patients with PAD may be asymptomatic but others suffer many medical issues such as claudication, ischemic rest pain, ischemic wounds, repeated revascularizations and limb loss.⁴ These symptoms can lead to a general decline in health status, poor quality of life and decreased abilities to perform both ADLs and IADLs (see Table 2).

Consultation with a vascular surgeon and vascular studies should be considered early in treatment of leg wounds and symptoms of PAD to decrease morbidity, improve quality of life and address issues with pain. The vascular surgeon can determine if bypass surgery or computed tomography angiography (CTA), with or without angioplasty, might be required if there is blockage in the main arterial vessels versus the distal peripheral vessels.

In our patient's case, it was determined that a CTA with angioplasty was indicated. The CTA showed that in the left leg that there was severe tibial arterial disease and superficial arterial stenosis and occlusion (see Figure 4). All were opened

Table 2. Activities of Daily Living and Instrumental Activities of Daily Living.⁵

ACTIVITIES OF DAILY LIVING (ADLs) Mnemonic - DEATH	INSTRUMENTAL ACTIVITIES OF DAILY LIVING (IADLs) Mnemonic - SHAFT
D - Dressing	S - Shopping
E - Eating	H - Housekeeping
A - Ambulating	A - Accounts
T - Toileting	F - Food Preparation
H - Hygiene	T - Telephone

by angioplasty to provide continuous flow to the angiosomes of the lesions (see Figure 4). The procedure was well-tolerated by our 97 patient and done under local anesthetic as a day procedure.

Angiosomes

The concept of angiosomes was introduced by Dr. Ian Taylor in 1987 and is now used in the fields of vascular surgery, plastic surgery and wound management.⁶ It is a concept that helps explain the relationship between arteries and the tissue territories they supply.⁶ An angiosome is a three-dimensional area of tissue containing skin, fat and muscle that is supplied by a source artery and drained by specific veins.

An understanding of angiosomes is important in vascular procedures to help improve wound healing by allowing the vascular surgeon to direct revascularization efforts to the territory supplying the wound.⁷

The arterial supply to the leg consists of six angiosomes which originate from three tibial arteries and their branches (see Figure 5):

1. **Anterior tibial artery** supplying the dorsum of the foot.
2. **Peroneal artery** supplying the lateral portion of the foot with some contribution to the heel.
3. **Posterior tibial artery** supplying the plantar surface of the foot. The posterior tibial artery further divides into a medial plantar, lateral plantar and calcaneal branch which supply the medial plantar surface, lateral plantar surface and the heel respectively.

Adjacent angiosomes are anatomically linked through choke vessels and direct arterial-arterial connections, establishing a unified network wherein a single source artery can supply multiple angiosomes.⁷ This arrangement allows blood to bypass interruptions within the vascular tree.⁷ While direct in-line flow is preferred, the redundancy in lower extremity perfusion allows for multiple lower extremity revascularization options when perfusion through the specific angiosome supplying a wound cannot be restored.⁷

Why Might Some Older Adults Not Be Sent To Vascular Surgery For Assessment of PAD?

Ageism is the discrimination or stereotyping of individuals based on their age. Health-care providers may misinterpret or downplay the symptoms of PAD in their older adult patients attributing the symptoms to aging or other factors. Health-care providers should be educated about the prevalence of PAD in older adults and the potential benefits of angioplasty.

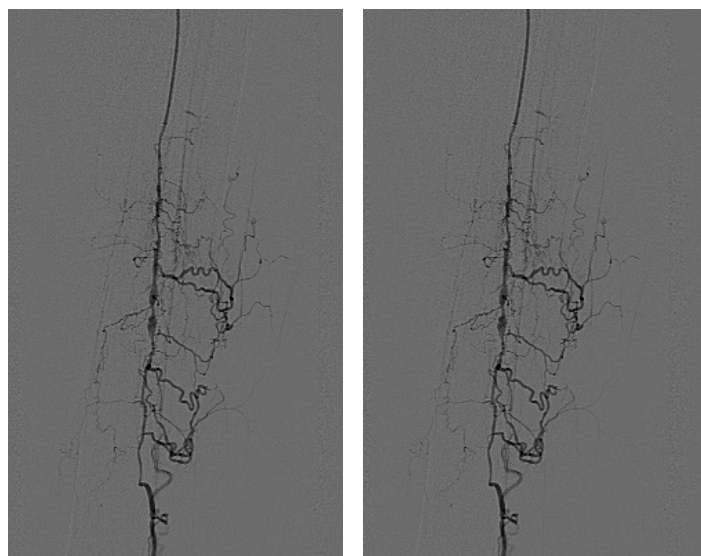


Figure 4. Lower extremity angiograms. Pre-procedure (left, ABI=0.28); Post-procedure (right, ABI=0.57).

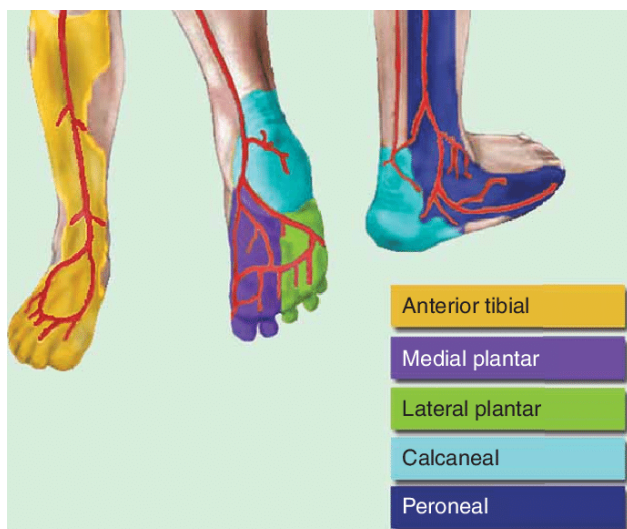


Figure 5. The Angiosome concept: Illustration of the lower extremity angiosomes represented as a topographic map divided into five territories, supplied by the three main arteries and their branches.⁸

Back To Our Patient...

All the patient's wounds healed over a period of five months and pain resolved. The patient was able to return to her previous mobility status – walking around the long-term care home using her walker and accompanying her friend, a fellow resident. Her mood also greatly improved and she was able to return to attending recreational functions at the home. Surgical intervention leading to subsequent healing led to a significant improvement in her overall quality of life.

She had not been referred to vascular surgery for the first six months of her treatment and this delay could have led to a permanent decrease in her functional capacity. She died at age 101 of another unrelated short illness. 🚫

Carol Ott MD FRCPC is a geriatrician practicing wound care and geriatrics at Baycrest and Women's College Hospital and Assistant Professor, Department of Medicine, University of Toronto.

Kennedy Ayoo MD is a Vascular Surgery resident, University of Toronto.

Andrea Moser MD MSc CCFP FCPC (COE)

CMD is Corporate Medical Director, City of Toronto, Seniors Services and Long-Term Care Division and Associate Professor, Department of Family and Community Medicine, University of Toronto.

Giuseppe Papia MD MSc FRCSC FRSCS

is a Vascular Surgeon, Sunnybrook Health Science Centre and Associate Professor and Chair of the Division of Vascular Surgery in the Department of Surgery, University of Toronto.

References

- Robertson L, Paraskevas KI, Stewart M. Angioplasty and stenting for peripheral arterial disease of the lower limbs: An overview of Cochrane Reviews. *Cochrane Database Syst Rev* [Internet]. 2017 Feb 1;2017(2): CD012542. DOI: 10.1002/14651858.CD012542. PMID: PMC6464525.
- Peach G, Griffin M, Jones KG, Thompson MM, Hinchcliffe RJ. Diagnosis and management of peripheral arterial disease. *BMJ*. 2012;345: e5208.
- Ostchega Y, Paulose-Ram R, Dillon CF. Prevalence of peripheral arterial disease and risk factors in persons aged 60 and older: Data from the National Health and Nutrition Examination Survey 1999-2004. *J Am Geriatr Soc* [Internet]. 2007 Apr;55(4): 583-9. Available from: <https://pubmed.ncbi.nlm.nih.gov/17397438/> DOI: 10.1111/j.1532-5415.2007.01123.x.
- Olin JW, Sealove BA. Peripheral artery disease: Current insight into the disease and its diagnosis and management. *Mayo Clin Proc* [Internet]. 2010 Jul;85(7): 678-920. Available from: <https://pubmed.ncbi.nlm.nih.gov/20592174/> DOI: 10.4065/mcp.2010.0133.
- Institutional training materials. Data on file.
- Taylor GI, Palmer JH. The vascular territories (angiosomes) of the body: Experimental study and clinical applications. *Br J Plast Surg* [Internet]. 1987 Mar;40(2): 113-41. Available from: <https://pubmed.ncbi.nlm.nih.gov/3567445/> DOI: 10.1016/0007-1226(87)90185-8.
- Attinger CE, Evans KK, Bulan E, Blume P, Cooper P. Angiosomes of the foot and ankle and clinical implications for limb salvage: reconstruction, incisions, and revascularization. *Plast Reconstr Surg* [Internet]. 2006 Jun;117(7 Suppl):261S-293S. Available from: <https://pubmed.ncbi.nlm.nih.gov/16799395/> DOI: 10.1097/01.prs.0000222582.84385.54
- Dominguez III A, Bahadorani J, Reeves R, Mahmud E, Patel M. Endovascular therapy for critical limb ischemia. *Expert Review of Cardiovascular Therapy*. 2015;13(4): 1-16 DOI:10.1586/14779072.2015.1019472