

# Larval Debridement Therapy in Mexico

BY JOSÉ Contreras-Ruiz, Adan Fuentes-Suarez, Marcia Karam-Orantes, Maria de Lourdes Escamilla-Mares and Judith Domínguez-Cherit

**T**he benefit of maggots in wound healing has probably been known to humankind for ages. In Mexico, healers and herbalists comment, mainly through oral tradition, that maggots were known by the ancient Mayan culture to be beneficial in infected necrotic wounds. However, no written evidence indicates that they were actually placed deliberately on the wounds.<sup>1</sup>

Among the earliest records of the benefit of maggots in wounds are those from Ambroise Paré (1517–1590), D.J. Larrey, Napoleon's chief surgeon (1766–1842), and J. Jones and J.F. Zacharias during the American Civil War (1861–1865).<sup>2-5</sup> All of these physicians during different wars recorded in their memoirs and reports that those patients who were infested with maggots did not develop gangrene; however, none of them purposely treated patients to this end.

It wasn't until 1928 that William Baer, an orthopaedic surgeon who had served in World War I and was later based at Johns Hopkins, decided to treat patients for osteomyelitis with sterile maggots. This was the first time that maggots were introduced in the medical literature.<sup>6-9</sup> Baer and one of his co-workers, S.K. Livingston, perfected the disinfection and application of maggots<sup>5,10</sup> and, given that antibiotics were not readily available at that time,

maggots became such a popular treatment that even a pharmaceutical company began distributing them.<sup>3,8</sup> With the arrival of antibiotics and better surgical techniques, the interest in maggot debridement therapy (MDT) gradually disappeared in the early 1940s.

Our wound-care centre at Hospital General "Dr.

Manuel Gea González" first became interested in this therapy in 2001. As we were searching for new developments and evidence in wound care, we encountered additional literature on maggots, including an old paper by Sherman et al.<sup>11,12</sup> where maggots had been reintroduced to medical practice by his group with the idea of having an alternative to antibiotic abuse. As described by these

authors, maggots possessed potent enzymes that could liquefy necrotic tissue, competed with bacteria, and secreted substances that could destroy bacteria. Reports also exist on maggots treating methicillin-resistant *Staphylococcus aureus* in wounds.<sup>13-15</sup> As we became more interested in the topic, the following passage caught our attention in one of the papers:

"Maggot therapy offers several advantages to conventional wound care in rural and tropical regions of the world, where highly skilled surgeons, technologically advanced resources, or even electricity may not be readily available. However, we are not aware of maggot therapy now ongoing in any other countries, except perhaps as isolated events."<sup>16</sup>



The Hospital General "Dr. Manuel Gea González," a National University of Mexico-affiliated teaching hospital. The wound-care centre is based within the Department of Dermatology, and wound care is taught as part of the dermatology residence.



The medicinal maggot logo.

**José Contreras-Ruiz, MD**, graduated from Universidad La Salle in Mexico and has served internships and residencies at Jackson Memorial Hospital, Miami; Department of Dermatology, National Institute of Pediatrics, Mexico City; Hospital Angeles del Pedregal and Hospital General "Dr. Manuel Gea González," Mexico City. He is currently completing a wound-care fellowship at Women's College in the department of dermatology at the Dermatology and Wound Care Daycare Centre in Toronto.

This obviously appealed to our socioeconomic reality, so we decided to test the idea. Our experiment with MDT began.

### The Process

At the beginning of 2002, we captured numerous species of flies using homemade fly traps. Not all species are suitable for MDT because they invade living tissue. With the aid of an expert entomologist at the National University of Mexico, we selected the proper non-harmful species, *Lucilia sericata*.

We then manufactured a homemade cage using acrylic panels, fine weave tulle fabric, and silicone. The amount spent up to this point of the project was only about \$80 (all figures in Canadian dollars). The fly cage kept the species from contamination with fruit flies or other sarcophagic insects. Breeding maggots was also very cheap (\$2 per week) since all they needed was water, sugar and a piece of liver, as per information published elsewhere.<sup>17</sup>

We then had to sterilize the eggs to prevent contamination of wounds. This has been a complication reported with the use of non-sterile maggots.<sup>18</sup>

To assist us with sterilization, we contacted the microbiology department at our hospital (Hospital General "Dr. Manuel Gea González"), who then became involved in the process. Instead of chlorine, we used orthophtaldehyde for eight minutes to disinfect the surface of the eggs and placed them in blood agar for future use. This is just a minor modification from the method that has been described in the literature.<sup>5,8,10,19</sup> Once the technique had been optimized and we had established proper microbiology controls

to prevent contamination, we decided to treat the first patient.

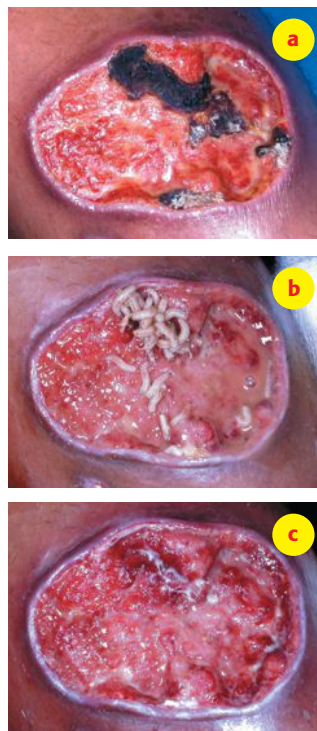
### Treatment Begins

In July 2002, we treated the first patient, a woman who came to us for a very painful venous ulcer

covered with areas of hard eschar. We thoroughly explained the method to her, and she consented to trying it for 24 hours. To our fascination, after 24 hours the wound bed looked clean and the eschar had been debrided (see pictures below).

After that, we started treating all types of ulcers with varying degrees of success. As the word spread about our centre using MDT, the media became interested in the topic, and we participated in several programs on national television. After that, more patients became interested in the therapy and came to our centre requesting treatment. As a result of the attention, our centre became flooded with patients requesting MDT, and we have never had to talk a patient into treatment since. Additional media coverage helped educate the public (and patients)

and dispel the misinformation about the treatment.



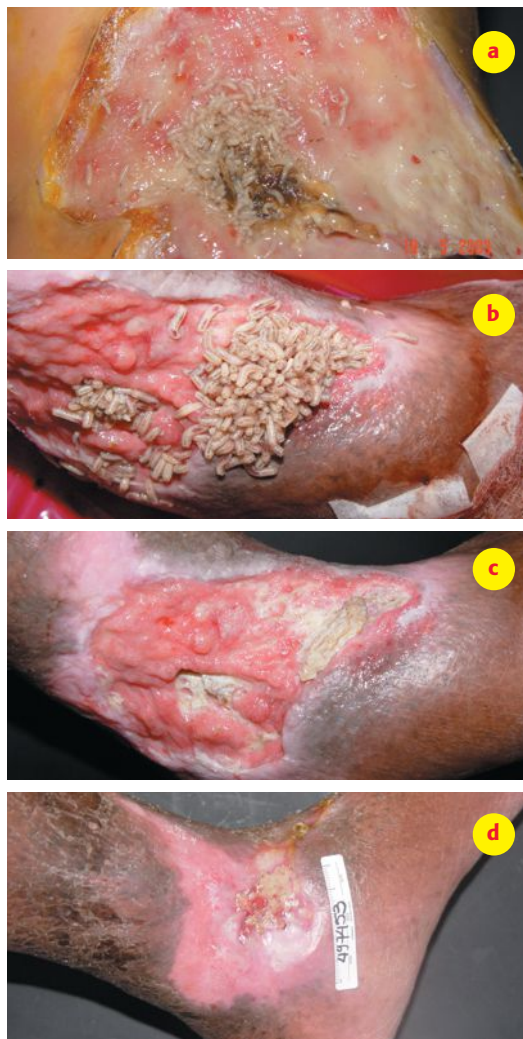The first patient treated at the centre with MDT. a) Before treatment. b and c) After 24 hours of therapy.

### A Maggot Shortage

The number of patients became overwhelming, and we started suffering a shortage of maggots because the flies were not laying enough eggs. As more very ill patients arrived requesting MDT, we had to start using eggs normally destined for enlarging our fly population. Eventually, the number of flies decreased, and we ran into a vicious cycle that almost brought the project to an end. We needed more flies. We devised new cages

and solved that issue, but then sterilization became our limiting factor since the microbiology department was now using up time dedicated to clinical work for the process of egg disinfection. A group meeting was held, and we worked together to optimize the process even more by disinfecting more eggs together. This gave us time to think about further steps to take.

By now, we had been contacted by several



Another patient treated with MDT. a) Before treatment. b) Application of the maggots in the wound. c) After 48 hours immediately after opening the cage-dressing. d) Wound after cleansing. Note the healthy granulation tissue present at the wound base.

researchers interested in the basic research and breeding of maggots. As maggots are not patented and can be bred by anyone, we were happy to share our experience. Now, we have two outside providers of medicinal maggots that cost only \$40 per vial of 500–1,000. This has allowed the microbiology department to stop producing maggots. And although patients now have to pay for their treatment, two patients can share one vial, and the cost becomes only \$20 per treatment in a public hospital setting.

### The Present


Between 2001 and 2005, we have applied more than 200 cycles of MDT. In our facility (a public general teaching hospital), MDT has now been accepted as another method of debridement by hospital authorities, patients and staff. We have treated venous, pressure and diabetic foot ulcers with excellent results. We have since acquired important experience on which subsets of patients benefit more and which patients would potentially be harmed by MDT.

We consider proper selection of the patients the most important issue to achieve these results. We do not treat patients with inadequate vascular supply (unless the patient understands that healing is not the goal), patients with bone infection (unless we apply maggots to “clean” the bone before surgical removal), or any other contraindications to MDT that have been recommended in the literature.<sup>7,20-24</sup> [See the Web Connect on page 42 for more information on contraindications.] As with any other type of debridement, established guidelines on debridement must be followed.

MDT has provided an alternative to the amputations that are so common for people with wounds in our country. Sadly, we still live in an era where amputation is believed to “save money to the system.” In our practice, most of these patients are rendered inoperable because operation suites are too crowded to perform major surgical debridements. The good news is

# PRESSURE RELIEF MATTRESS

**DYNAMIC & ECONOMICAL PRESSURE RELIEF  
WITH OR WITHOUT A CONTROL UNIT!**



**AccuMax**  
QUANTUM CONVERTIBLE  
Pressure Relief System



**10 Laterally positioned  
inter connected  
air sectors**



**6 Anatomically  
inspired pressure  
relief zones**



**Patented  
heel pillow  
with heel slope**



9100 Ray Lawson Blvd  
Anjou, QC H1J 1K8  
Tel. : (514) 356-1224 / Fax : (514) 356-0055  
Toll Free : (800) 361-4964  
[www.mipinc.com](http://www.mipinc.com)



that many of the patients who were scheduled for amputation have been healed with MDT and proper wound care.

The usefulness of MDT has extended beyond Mexico City, and now specialists in Monterrey, Guadalajara, Veracruz and Tampico are using MDT as another method of debridement.

### The Future

Now that MDT has a place in the Mexican wound-care armamentarium and is widely used, we felt the need to demonstrate the evidence of its benefit compared with standard care. There are some randomized controlled trials on the subject in the literature comparing MDT with enzymatic, autolytic and mechanical debridement and indicating MDT as faster, safer and more efficient. We are currently in the process of publishing our results comparing MDT with standard surgical curettage and application of silver in venous ulcers. We are also undergoing two more trials on diabetic foot ulcers and pressure ulcers. One of the main difficulties in performing this type of research is that funding has to come from our own pockets, since no outside resources are available.

In the future, we plan to continue performing trials and analyzing the literature on the topic to try to establish proper guidelines for use as well as indications and contraindications that will help clinicians in other areas of the country and in other developing countries in the proper selection of patients who would benefit the most from MDT. ☺

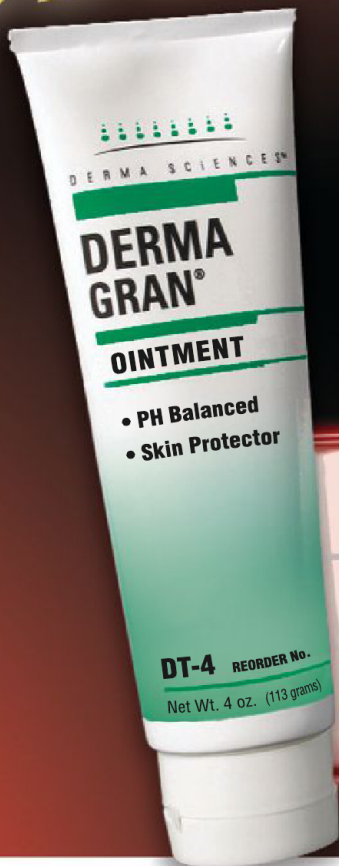### References

- Weil GC, Simon RJ, Sweadner WR. A biological, bacteriological and clinical study of larval or maggot therapy in the treatment of acute and chronic pyogenic infections. *Am J Surg*. 1933;19:36-48.
- The Apologie and Treatise of Ambroise Paré*. Chicago: The University of Chicago Press. 1952.
- Chernin E. Surgical maggots. *South Med J*. 1986;79:1143-1145.
- Larrey DJ. Des vers ou larves de la mouche bleue. *Clin Chir*. 1829;1:51.
- Wollina U, Karte K, Herold C, Looks A. Biosurgery in wound healing—the renaissance of maggot therapy. *J Eur Acad Dermatol Venereol*.

2000;14:285-289.

- Baer W. The treatment of chronic osteomyelitis with the maggot (larva of the blow fly). *J Bone Joint Surg*. 1931;13:438-475.
- Jones M, Thomas S. Larval therapy. *Nurs Stand*. 2000;14:47-51.
- Mumcuoglu KY, Ingber A, Gilead L, et al. Maggot therapy for the treatment of diabetic foot ulcers. *Diabetes Care*. 1998;21:2030-2031.
- Thomas S, Jones M, Andrews A. Special focus: tissue viability. The use of fly larvae in the treatment of wounds. *Nurs Stand*. 1997;12:54, 57-54,59.
- Livingston SK. Maggots in the treatment of chronic osteomyelitis, infected wounds and compound fractures. *Surg Gynecol Obstetr*. 1932;54:702-706.
- Pechter EA, Sherman RA. Maggot therapy: The surgical metamorphosis. *Plast Reconstr Surg*. 1983;72:567-570.
- Sherman RA, Pechter EA. Maggot therapy: A review of the therapeutic applications of fly larvae in human medicine, especially for treating osteomyelitis. *Med Vet Entomol*. 1988;2:225-230.
- Beasley WD, Hirst G. Making a meal of MRSA—The role of biosurgery in hospital-acquired infection. *J Hosp Infect*. 2004;56:6-9.
- Dissemond J, Koppermann M, Esser S, Schultewolter T, Goos M, Wagner SN. Treatment of methicillin-resistant *Staphylococcus aureus* (MRSA) as part of biosurgical management of a chronic leg ulcer. *Hautarzt*. 2002;53:608-612.
- Thomas S, Andrews AM, Hay NP, Bourgoise S. The anti-microbial activity of maggot secretions: Results of a preliminary study. *J Tissue Viability*. 1999;9:127-132.
- Sherman RA, Hall MJR, Thomas S. Medicinal maggots: An ancient remedy for some contemporary afflictions. *Ann Rev Entomol*. 2000;45, 55-81.
- Sherman RA, Wyle FA. Low-cost, low-maintenance rearing of maggots in hospitals, clinics, and schools. *Am J Trop Med Hyg*. 1996;54:38-41.
- Rufli T, Steffen I, Nuesch R. Sepsis as a complication of maggot therapy. Fifth International Conference on Biotherapy. 2004. Wurzburg, Germany.
- Mumcuoglu KY, Ingber A, Gilead L, et al. Maggot therapy for the treatment of intractable wounds. *Int J Dermatol*. 1999;38:623-627.
- Bonn D. Maggot therapy: An alternative for wound infection. *Lancet*. 2000;356:1174.
- Courtenay M, Church JC, Ryan TJ. Larva therapy in wound management. *J R Soc Med*. 2000;93:72-74.
- Mumcuoglu KY. Clinical applications for maggots in wound care. *Am J Clin Dermatol*. 2001;2:219-227.
- Sherman RA. Maggot debridement in modern medicine. *Infect Med*. 1998;15:651-656.
- Sherman RA. Maggot therapy for foot and leg wounds. *Lower Extremity Wounds*. 2002;1:135-142.

*STARRING*



**A MARKET  
LEADER FOR  
20 YEARS!**

**EASY TO  
APPLY AND  
REMOVE**

**THINK ZINC FOR  
OPTIMAL SKIN  
INTEGRITY**

## **IS DERMAGRAN® A STAR IN YOUR WOUND CARE / SKIN CARE FORMULARY?**

**Maybe it should be.** DermaGran Ointment pioneered the field of topical nutritional wound healing and skin integrity. Its proprietary zinc nutrient formulation has been used successfully for over 20 years!

**DERMAGRAN® IT WORKS.**



DERMA SCIENCES 1-800-387-5302 • [www.dermasciences.com](http://www.dermasciences.com)

104 Shorting Road, Toronto, Ontario, Canada. M1S 3S4

